

Comparison of Magnetic Resonance Imaging Findings in Anterior Cruciate Ligament Grafts With and Without Autologous Platelet-Derived Growth Factors

Fernando Radice, M.D., Roberto Yáñez, M.D., Vicente Gutiérrez, M.D., Julio Rosales, M.D., Miguel Pinedo, M.D., and Sebastián Coda, M.D.

Purpose: To determine whether the use of platelet-rich plasma gel (PRPG) affects magnetic resonance imaging (MRI) findings in the anterior cruciate ligament (ACL) graft during the first year after reconstruction. **Methods:** A prospective single-blinded study of 50 ACL reconstructions in 50 patients was performed. In group A (study group) PRPG was added to the graft with a standardized technique, and in group B (control group) no PRPG was added. An MRI study was performed postoperatively between 3 and 9 months in group A and between 3 and 12 months in group B. The imaging analysis was performed in a blind protocol by the same radiologist. **Results:** The mean heterogeneity score value at the time of MRI, assigned by the radiologist, was 1.14 in group A and 3.25 in group B. Both groups were comparable in terms of sex and age ($P < .05$). The mean time to obtain a completely homogeneous intra-articular segment in group A (PRPG added) was 177 days after surgery, and it was 369 days in group B. Using the quadratic predictive model, these findings show that group A (PRPG added) needed only 48% of the time group B required to achieve the same MRI image ($P < .001$). **Conclusions:** ACL reconstruction with the use of PRPG achieves complete homogeneous grafts assessed by MRI, in 179 days compared with 369 days for ACL reconstruction without PRPG. This represents a time shortening of 48% with respect to ACL reconstruction without PRPG. **Level of Evidence:** Level III, case-control study.

Rupture of the anterior cruciate ligament (ACL) is an injury commonly observed in sports medicine. Return to professional sports occurs at around 6 to 7 months, depending on the sport practiced. In sports medicine this time period is often very long

for the athlete; thus methods have been sought to shorten the biological time required for the graft to acquire biomechanical properties similar to the original ACL.

The clinical results of ACL reconstruction and time to return to sports could be improved if the graft healing process is enhanced. In a classic publication on this topic in 1982, Arnoczky and Tarvin¹ described the behavior of the graft used in ACL reconstruction in dogs, describing 3 stages in the process of graft metaplasia: incorporation, neoligament formation, and remodeling.^{2,3}

Various authors have tried to study the behavior of the graft in clinical trials, with histology or imaging studies, which experienced a significant boost with the appearance of magnetic resonance imaging (MRI).⁴⁻¹⁰

In 1995, in a prospective clinical study that relied on second-look arthroscopy to perform a histologic and MRI assessment of the graft at 6, 9, and 12 months of postoperative evolution,¹¹ we described

From the Department of Orthopedics and Sports Medicine, Clínica Las Condes (F.R., V.G., M.P.), and Departments of Sports Medicine (R.Y., S.C.) and Radiology (J.R.), Clínica MEDS: Medicina, Ejercicio, Deporte y Salud, Santiago, Chile.

Presented at the Biannual Meeting of the Sociedad Latinoamericana de Artroscopia Rodilla y Traumatología Deportiva, Cancún, Mexico, June 5-7, 2008.

The authors report no conflict of interest.

Received August 24, 2008; accepted June 30, 2009.

Address correspondence and reprint requests to Fernando Radice, M.D., Department of Orthopedics and Sports Medicine, Clínica Las Condes, Lo Fontecilla 441, Santiago 6772610, Chile. E-mail: fradice@clc.cl

© 2010 by the Arthroscopy Association of North America

0749-8063/10/2601-8486\$36.00/0

doi:10.1016/j.arthro.2009.06.030

how the patellar tendon graft used in human ACL reconstruction is incorporated. We concluded that the graft maturation takes a long time: 12 months to achieve histology similar to a normal ACL. At 12 months, the MRI study of the graft was homogeneous and hyperintense, without swelling in the bone tunnels. The correlation of the histology with MRI was of great help in establishing a reliable imaging pattern, which allowed us to noninvasively verify the graft healing process.

Weiler et al.¹² report correlations between biomechanical properties and vascularity of an ACL graft and MRI in a sheep model.

Clinical applications of autologous platelet-rich plasma gel (PRPG) include maxillofacial surgery, treatment of bone fractures, and tendon repair, reporting excellent outcomes.¹³⁻¹⁶ Platelets contain different growth factors that facilitate healing. PRPG is a fraction of plasma volume with a platelet concentration above baseline (whole blood). Platelet concentrates contain an enormous amount of activated platelet-derived growth factors (PDGFs).¹⁷⁻²³

Platelets contain PDGFs, transforming growth factors (TGFs), insulin-like growth factors, epidermal growth factors, vascular endothelial growth factors, and fibroblast growth factors. These factors are involved in the majority of biological remodeling processes in the body. In the specific case of ACL graft, PDGFs, fibroblast growth factor 1, and the various types of TGF- β are responsible for accelerating the healing process, as well as increasing the tensile strength of the graft.²⁴⁻³⁰

Only 2 articles have shown an enhancing effect of treatment with PRPG on the tendon or ligament in humans. In a human study Orrego et al.³¹ showed an enhancing effect over the graft maturation process as evaluated by MRI signal intensity, without showing a significant effect on the osteoligamentous interface or tunnel widening evolution. In human tenocyte cultures, de Mos et al.³² showed that PRPG stimulates cell proliferation and collagen production.

Currently, it is practically impossible to perform human clinical trials of biomechanical or histologic assessments of the graft's behavior in ACL reconstruction. For this reason, we decided to practice an indirect and noninvasive assessment in our patients, using MRI. The purpose of our investigation was to study MRI findings in the ACL graft when PRPG was added during surgery, thus allowing future studies correlating MRI findings with histology and ultimate load and strength. We hypothesized that PRPG has a positive effect on cell proliferation and collagen pro-

duction in the human tendon and plays a key role in the remodeling and repair processes of the graft used in ACL reconstruction.

METHODS

Study Design

This is a prospective and single-blinded study performed between June 2005 and December 2006. The inclusion criteria were sport athletes of both gender between 18 and 35 years old with an isolated ACL tear shown by MRI. Exclusion criteria were previous ACL revision surgery, chronic or systemic disease under treatment, and previous or current treatment for malignant disease. These pathologies can modify the biologic behavior of the graft. Fifty consecutive patients met the inclusion criteria.

The type of graft used was determined according to our institution's protocol, and it depended on the type of sports the patient practiced. Bone-patellar tendon-bone (BPTB) autograft was used in rugby and soccer players, whether hamstring autograft was used in players who practiced skiing, hockey, tae kwon do, and volleyball. One of the surgeons (R.Y.) did not use PRPG, and the other (F.R.) did. Two groups were established: Group A included 25 patients (18 men and 7 women), with a mean age of 30 years (range, 18 to 33 years), with ACL reconstruction plus PRPG; 15 of these patients underwent reconstruction with BPTB. Group B included 25 patients (21 men and 4 women), with a mean age of 32 years (range, 18 to 35 years), with ACL reconstruction without PRPG; 10 of these patients underwent reconstruction with hamstring autografts. Both groups (A and B) followed the same rehabilitation protocol.

Surgical Technique

In the case of BPTB autograft, fixation was performed with metallic interference screws. Hamstring autograft fixation was performed with metallic or bioabsorbable cross-pin femoral fixation using the Trans-Fix technique (Arthrex, Naples, FL) in the distal femur and a Delta-type bioabsorbable screw with a metallic staple in the proximal tibia (Arthrex).

In group A PRPG was administered by an application technique developed to allow standardization of the dose of concentrate used and avoidance of its loss when the graft goes through the bone tunnels.^{33,34} The autologous platelet concentrate was obtained from the GPS system of Biomet (Warsaw, IN). This procedure is done aseptically in the same operating room. Pre-

operatively, 60 mL of autologous blood is obtained and centrifuged at 3,200 rpm for 15 minutes. In the case of BPTB graft, after adaptation of the bone plugs for them to fit through the tunnels, the femoral bone segment and the intra-articular segment are wrapped with a bioabsorbable synthetic gelatin called Gelfoam (Pfizer, New York, NY) and secured to it with a No. 3-0 Vicryl suture (Ethicon, Somerville, NJ). In the case of hamstring tendon graft, it is prepared in the usual manner with removal of the remnant muscle tissue. At each end, a 3-cm-long braid with FiberWire (Arthrex) is made, and the tendon's thickness and length are measured. Under moderate tension, a piece of Gelfoam is placed between the portion of the tendons that will be located in the femoral tunnel and the intra-articular segment. This is sutured to the adjacent tendon with No. 3-0 Vicryl. The Gelfoam acts as a sponge that maintains the platelet concentrate dose in direct contact with the graft (Fig 1). A total volume of 5 mL of platelet-rich plasma, activated at the moment of inoculation on the graft, is added homogeneously so as to completely cover the graft, waiting until it forms a clot (Fig 2). The dose administered was determined based only on our criteria. We do not know the ideal dose, and at the time of this study, nothing about the ideal dose had been published. The formed clot adheres to the graft, because of the presence of the sutured and compressed Gelfoam. This allows the graft to hold a precise amount of PRPG and, even more importantly, avoids the loss of PRPG when the graft goes through the bone tunnels (Fig 3).

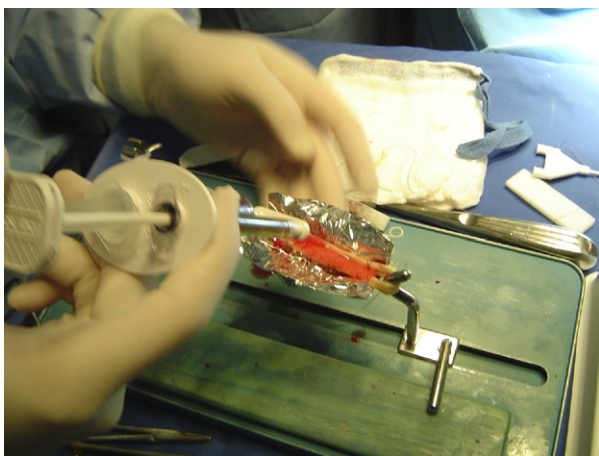


FIGURE 1. Hamstring graft preparation with Gelfoam and PRPG.

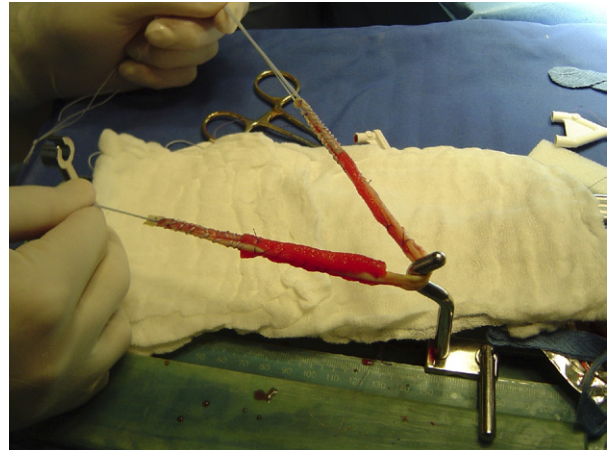


FIGURE 2. The Gelfoam acts as a sponge that maintains the PRPG dose in direct contact with the graft.

Imaging Assessment

The imaging protocol was standardized and similar in both groups. Included were a series of MRI scans focused to study the intra-articular segment of the graft. The study of the femoral and tibial parts of the graft was not considered because its maturation process occurs first, compared with the intra-articular part. This was performed with a T1 and T2 sequence (repetition time, 4,020 milliseconds; echo time, 105 milliseconds) with a 1.5-T Siemens Magnetom MRI Scanner (Siemens AG, Erlangen, Germany). Slices of 2 mm in thickness, in the oblique parasagittal view, between 10° and 15°, centered on the intercondylar region, with the knee flexed at 9° to 10°,¹¹ were obtained. Patients in group A had MRI performed at 3, 4, 5, 6, 7, 8, and 9 months postoperatively so as to build a homogenization curve of the graft, according to the statistic quadratic predictive model, and supported by this study's hypothesis that the use of PRPG accelerates the graft homogenization time. The control group had MRI performed at 6, 7, 8, 9, 10, 11, and 12 months, with the assumption that before 6 months, homogenization is not present.

The imaging analysis was done by the same radiologist, experienced in musculoskeletal studies, blinded to the time of reconstruction and to PRPG application to the graft.

The radiologist divided the intra-articular segment of the graft into 3 segments: proximal, medial, and distal. To each segment, he assigned a score according to the degree of heterogeneity observed. Therefore a score of 0 was assigned to an absolutely homogeneous

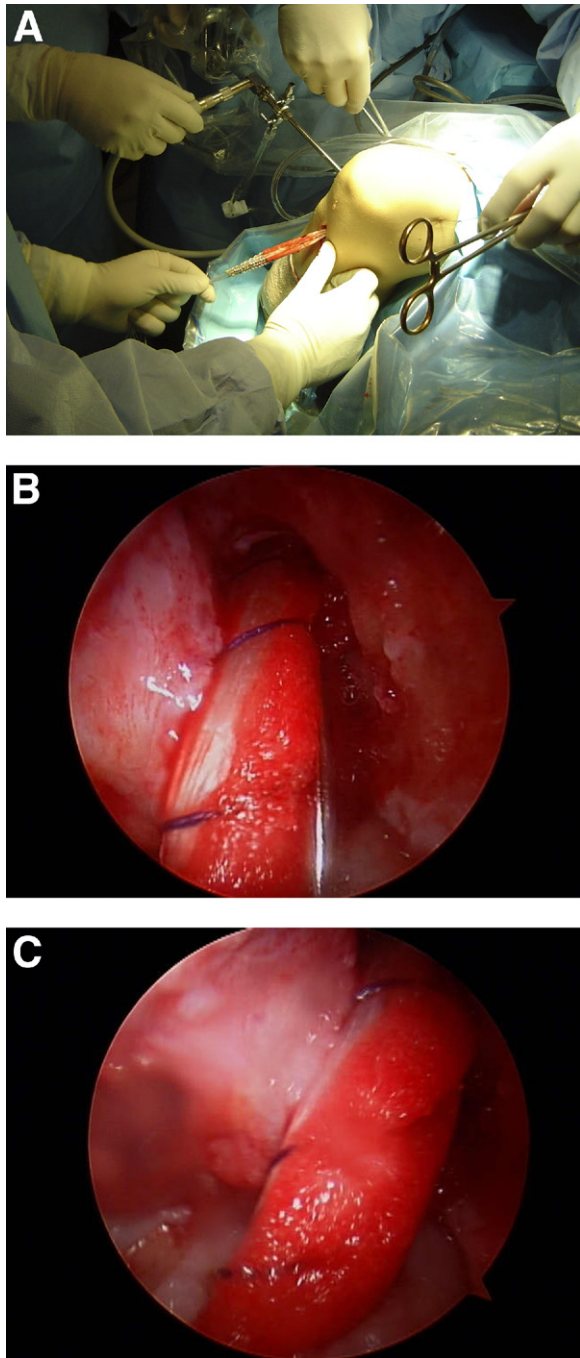


FIGURE 3. (A) To avoid the loss of the PRPG when the graft passes through the bone tunnels, the Gelfoam is placed between the prepared tendons. (B) Intra-articular visualization of ACL reconstruction with PRPG in BPTB graft. (C) Intra-articular visualization of ACL reconstruction with PRPG in hamstring graft.

segment (Fig 4); 1, slightly heterogeneous; 2, moderately heterogeneous; and 3, severely heterogeneous (Fig 5). A sum of the scores for each segment was

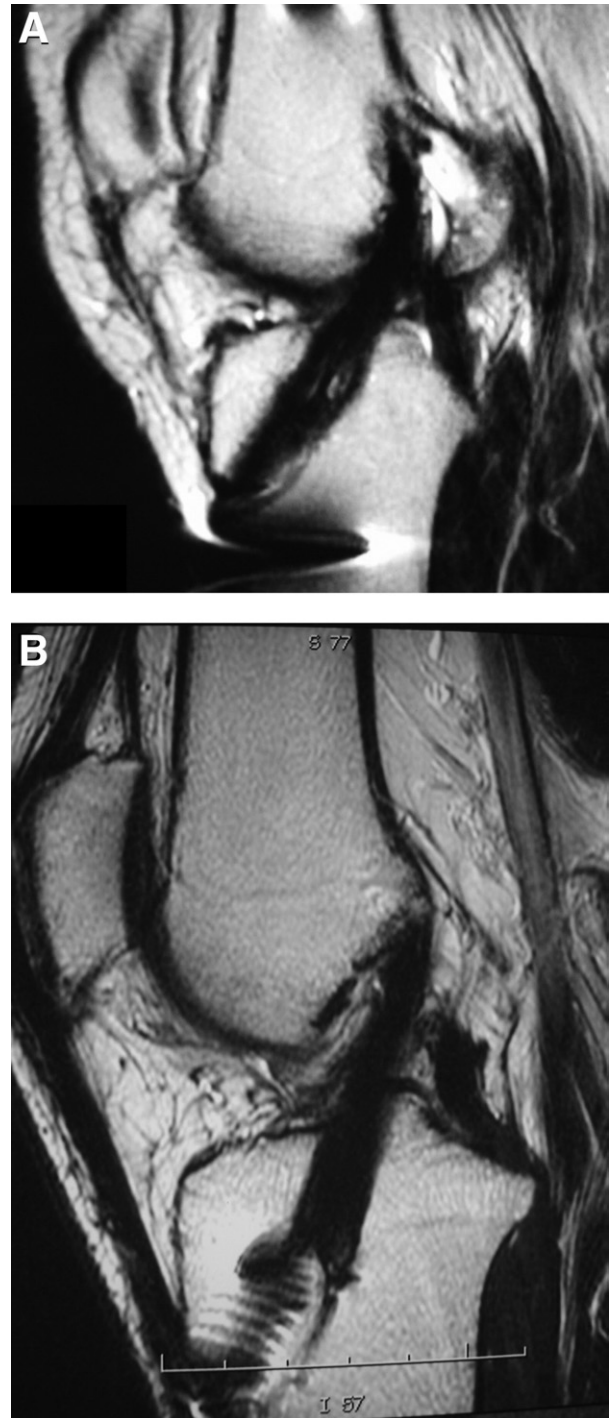


FIGURE 4. (A) MRI 6 months after ACL reconstruction: Hamstring graft with PRPG. A score of 0 was assigned to an absolutely homogeneous segment. (B) MRI 5 months after ACL reconstruction: BPTB graft with PRPG. A score of 0 was assigned to an absolutely homogeneous segment.

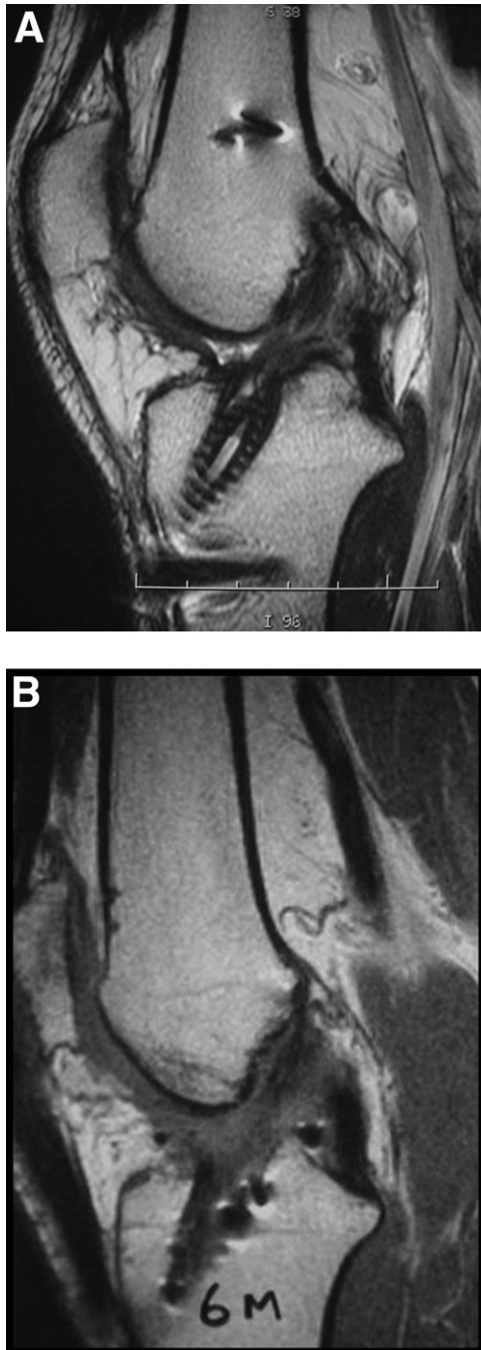


FIGURE 5. (A) MRI 6 months after ACL reconstruction: Hamstring graft without PRPG. A score of 3 was assigned to a severely heterogeneous segment. (B) MRI 6 months after ACL reconstruction: BPTB graft without PRPG. A score of 3 was assigned to a severely heterogeneous segment.

obtained for each patient, which was compared statistically between the 2 groups and correlated with the time at which the MRI study was done.

Statistic Analysis

For the statistic analysis, data were analyzed with the SPSS data analysis program (SPSS, Chicago, IL). This program was used to work with quadratic statistics, graphs, data, and descriptive indicators. To determine whether the 2 groups were comparable in terms of number, age, and sex, an *F* test and Student *t* test were used.

The quadratic predictive model was used for data analysis to determine, through a linear relation, the extrapolated midpoint that predicted the time when both groups had completely homogeneous grafts.

RESULTS

The mean heterogeneity score value at the time of MRI, assigned by the radiologist, was 1.14 in group A and 3.25 in group B. Both groups were comparable in terms of sex and age ($P < .05$). The mean time to obtain a completely homogeneous intra-articular segment in group A (PRPG added) was 177 days after surgery, and it was 369 days in group B. Using the quadratic predictive model, the percentage of time that group A (PRPG added) needed to achieve the same MRI aspect as group B was 48% (Fig 6). This fact is even more evident when we compared only the BPTB graft cases in both groups: a homogeneous graft was obtained in 109 days in patients with PRPG versus 363 days in the control group, that is, one third the time as that for control group (Fig 7). In the comparative analysis of those patients in whom BPTB graft was used, we observed an even shorter time required for the graft's homogenization when PRPG was used,

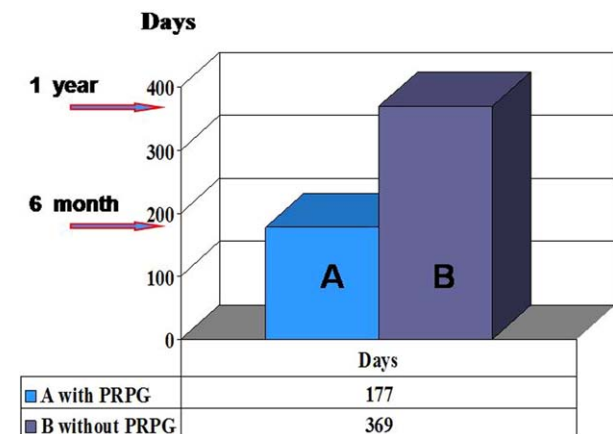


FIGURE 6. Homogenization of graft, by use of quadratic predictive model, in group A (with PRPG) versus group B (control).

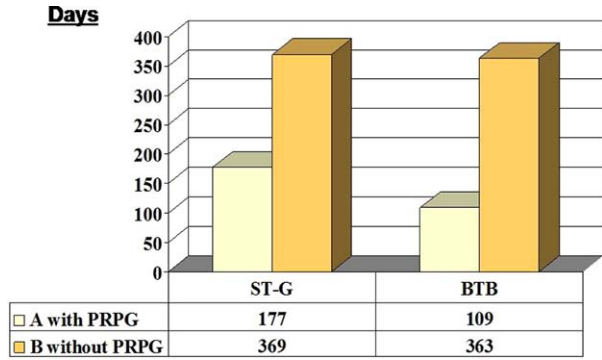


FIGURE 7. Homogenization of graft comparing BPTB and hamstring in group A (with PRPG) versus group B (control). (BPTB and hamstring without PRPG.)

but this can only be considered a trend, because the sample's number was too small to draw conclusions with statistical significance (β type error).

The latter fact, despite the large difference between the groups, merely shows a statistical trend, because it lacks statistical significance. On the other hand, to certify the findings of the quadratic model, in both groups only the patients who fully completed the requirements of a return to sports without restrictions, with normal functional sport-specific and isokinetic evaluations, were selected. The mean time to obtain an MRI score of 0, that is, a completely homogeneous graft, was compared between the groups (12 in the PRPG group and 6 in the control group). It was determined that the mean time in days to obtain a homogeneous graft was 179 days and 362 days in the PRPG and control groups, respectively (Fig 8). This finding indicates a decrease by half of the time (49.4%) in the group with PRPG versus the control group ($P < .001$). Once again, modifying the data analysis, the homogenization time of the intra-articular segment of the ACL graft evaluated with specific MRI slices is halved when growth factors, obtained through a standardized autologous platelet concentrate method, are used.

DISCUSSION

For elite athletes, recovery from ACL injury must reach a level close to normal and occur in the shortest time possible so as not to affect the future athletic performance. In the last decade great advances have occurred in ACL reconstruction surgery, considerably improving the outcomes. This is because of the development of more anatomic reconstruction techniques,

stronger and more stable methods of attachment over time, accelerated rehabilitation protocols, better technical training, and increased expertise of surgical teams. However, reinjury in these athletes, attributed to trauma in early periods of sports reintegration, clearly indicates that the biological period of maturation and metaplasia needed by the graft used in the reconstruction is not affected by the described advances. For the patellar tendon graft, this period is on average 9 to 12 months.^{2,11,14} Therefore, during the last years the focus of research has been on advancements in the basic sciences relating to the study of function and capacity for repair, as well as development of growth factors and tissue. Yasuda et al.,²⁸ analyzing the effect of growth factors applied to grafts in dog models, indicated that TGF- β and epidermal growth factor act by increasing the collagen and fibroblast synthesis by 40% in the graft. Anderson et al.¹⁴ indicated that the presence of TGF- β 1, TGF- β 2, TGF- β 3, and TGF-1 growth factors directly influences the graft by improving the scarring rate and increasing the tensile force resistance by 65%. In another interesting experimental study, Weiler et al.²⁷ indicate that the application of autologous PDGFs applied to the graft during surgery was capable of changing its natural evolution, improving tensile strength and resistance, increasing the maturation rate, and improving collagen quality. The results in our study showed a significant shortening of the biological maturation time of the graft, by at least 48%. Our results show that when PRPG is used, the time required by the graft to achieve complete homogenization, as assessed by MRI, is statistically shortened.

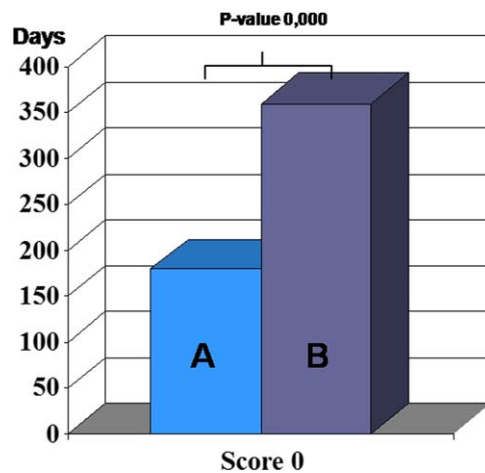


FIGURE 8. Comparison of only grafts with absolutely homogeneous segment in group A (with PRPG) versus group B (control).

This is very important for the graft's biological maturation. This means that the graft used with PRPG could undergo its complete process in half the time it naturally requires. We are performing a follow-up of all of our operated athletes to see what happened regarding reinjury, but the follow-up time is still short.

The use of the gelatin (Gelfoam) could affect the magnetic resonance image or analysis, but because it is absorbable, it may already be biodegraded at the time of imaging assessment. There are no studies in the literature describing local changes related to bone or tendon grafts. The early changes seen in the intra-articular segment of the graft with the use of PRPG suggest some effect on it. There are no published studies that relate the quality of the MRI signal intensity with histology or strength of grafts in human models. However, investigations by Weiler et al.¹² in sheep models showed that there is a correlation among the homogeneity of the graft on MRI, maturation, and strength, similar to the native ACL.

Much field to cover still remains. The current application of autologous PDGFs²²⁻²⁵ does not allow us to specifically isolate the factors related to the process. We are most likely applying a mixture of factors that apparently do not participate in or influence the healing process of these tissues.^{24-26,30,35,36} It is also not clear to us whether isolated application at the time of surgery is enough or whether it would be even more effective to repeat application of these factors during the postoperative recovery and rehabilitation process. Which are the growth factors that are actually needed in ACL reconstruction? Is the quantity we are applying adequate? Is it important to maintain the interaction and balance between all of the growth factors present in the platelet concentrate? How long does their effect last? We still do not have the answers to these questions, and further studies are required.

CONCLUSIONS

ACL reconstruction with the use of PRPG achieves completely homogeneous grafts, assessed by MRI, in 179 days compared with 369 days for ACL reconstruction without PRPG. This represents a time shortening of 48% with respect to ACL reconstruction without PRPG.

REFERENCES

1. Arnoczky SP, Tarvin GB. Anterior cruciate ligament replacement using patellar tendon: An evaluation of graft revascularization in the dog. *J Bone Joint Surg Am* 1982;64:217-224.
2. Falconiero RP, DiStefano VJ, Cook TM. Revascularization and ligamentization of autogenous anterior cruciate ligament grafts in humans. *Arthroscopy* 1998;14:197-205.
3. Kleiner JB, Amiel D, Harwood FL, Akeson WH. Early histologic, metabolic, and vascular assessment of anterior cruciate ligament autografts. *J Orthop Res* 1989;7:235-242.
4. Abe S, Kurosaka M, Iguchi T, Yoshiya S, Hirohata K. Light and electron microscopic study of remodeling and maturation process in autogenous graft for anterior cruciate ligament reconstruction. *Arthroscopy* 1993;9:394-405.
5. Grøntvedt T, Engebretsen L, Rossvoll I, Smevik O, Nilsen G. Comparison between magnetic resonance imaging findings and knee stability: Measurements after anterior cruciate ligament repair with and without augmentation. A five- to seven-year follow-up of 52 patients. *Am J Sports Med* 1996;23:729-735.
6. Howell SM, Clark JA, Blasier RD. Serial magnetic resonance imaging of hamstring anterior cruciate ligament autografts during the first year of implantation. *Am J Sports Med* 1991;19:42-47.
7. Maywood RM, Murphy BJ, Uribe JW, et al. Evaluation of arthroscopic anterior cruciate ligament reconstruction using magnetic resonance imaging. *Am J Sports Med* 1993;21:523-527.
8. Rougraff BT, Shelbourne KD. Early histologic appearance of human patellar tendon autografts used for anterior cruciate ligament reconstruction. *Knee Surg Sports Traumatol Arthrosc* 1999;7:9-14.
9. Unterhauser FN, Bail HJ, Höher J, Haas NP, Weiler A. Endoligamentous revascularization of an anterior cruciate ligament graft. *Clin Orthop Relat Res* 2003;276-288.
10. Yoshikawa T, Tohyama H, Enomoto H, Matsumoto H, Toyama Y, Yasuda K. Temporal changes in relationships between fibroblast repopulation, VEGF expression, and angiogenesis in the patellar tendon graft after ACL reconstruction. *Trans Orthop Res Soc* 2003;29:236.
11. Radice F, Gutierrez V, Ibarra A. Arthroscopic, histologic and MRI correlation in the maturation process of the graft in ACL reconstruction in humans. *Arthroscopy* 1998;14:S20 (Suppl 1). Abstracts presented at the First Biennial Congress of ISAKOS.
12. Weiler A, Peters G, Mäurer J, Unterhauser FN, Südkamp NP. Biomechanical properties and vascularity of an anterior cruciate ligament graft can be predicted by contrast-enhanced magnetic resonance imaging. A two-year study in sheep. *Am J Sports Med* 2001;29:751-761.
13. Hildebrand KA, Woo SL-Y, Smith DW, et al. The effects of platelet-derived growth factor-BB on healing of the rabbit medial collateral ligament. *Am J Sports Med* 1998;26:549-554.
14. Anderson K, Seneviratne AM, Izawa K, Atkinson BL, Potter HG, Rodeo SA. Augmentation of tendon healing in an intra-articular bone tunnel with use of a bone growth factor. *Am J Sports Med* 2001;29:689-698.
15. Jenner JM, van Eijk F, Saris DB, Willems WJ, Dhert WJ, Creemers LB. Effect of transforming growth factor-beta and growth differentiation factor-5 on proliferation and matrix production by human bone marrow stromal cells cultured on braided poly lactic-coglycolic acid scaffolds for ligament tissue engineering. *Tissue Eng* 2007;13:1573-1582.
16. Kondo E, Yasuda K, Yamanaka M, Minami A, Tohyama H. Effects of administration of exogenous growth factors on biomechanical properties of the elongation-type anterior cruciate ligament injury with partial laceration. *Am J Sports Med* 2005;33:188-196.
17. Lee J, Green MH, Amiel D. Synergistic effect of growth factors on cell outgrowth from explants of rabbit anterior cruciate and medial collateral ligaments. *J Orthop Res* 1995;13:435-441.
18. Letson AK, Dahners LE. The effect of combinations of growth

- factors on ligament healing. *Clin Orthop Relat Res* 1994;207-212.
19. Marui T, Niyibizi C, Georgescu HI, et al. Effects of growth factors on matrix synthesis by ligament fibroblasts. *J Orthop Res* 1997;15:18-23.
 20. Murray MM, Spindler KP, Abreu E, et al. Collagen-platelet rich plasma hydrogel enhances primary repair of the porcine anterior cruciate ligament. *J Orthop Res* 2007;25:81-91.
 21. Pierce GF, Mustoe TA, Lingelbach J, et al. Platelet-derived growth factor and transforming growth factor- β enhance tissue repair activities by unique mechanisms. *J Cell Biol* 2000; 109:429-440.
 22. Sanchez M, Anitua E, Azofra J, Andía I, Padilla S, Mujika I. Comparison of surgically repaired achilles tendon tears using platelet-rich fibrin matrices. *Am J Sports Med* 2007;35:245-251.
 23. Sánchez M, Azofra J, Aizpurua B, Elorriaga R, Anitua E, Andia I. Application in arthroscopic surgery of autologous plasma rich in growth factors. *Cuad Artrosc* 2003;10:12-19 (in Spanish).
 24. Anitua E, Andia I, Sanchez M, et al. Autologous preparations rich in growth factors promote proliferation and induce VEGF and HGF production by human tendon cells in culture. *J Orthop Res* 2005;23:281-286.
 25. Azuma H, Yasuda K, Tohyama H, et al. Timing of administration of transforming growth factor- β and epidermal growth factor influences the effect on material properties of the in situ frozen-thawed anterior cruciate ligament. *J Biomech* 2003;36:373-381.
 26. Sakai T, Yasuda K, Tohyama H, et al. Effects of combined administration of transforming growth factor- β 1 and epidermal growth factor on properties of the in situ frozen ACL in rabbits. *J Orthop Res* 2002;20:1345-1351.
 27. Weiler A, Förster C, Hunt P, et al. The influence of locally applied platelet-derived growth factor-BB on free tendon graft remodeling after anterior cruciate ligament reconstruction. *Am J Sports Med* 2004;32:881-891.
 28. Yasuda K, Tomita F, Yamazaki S, Minami A, Tohyama H. The effect of growth factors on biomechanical properties of the bone-patellar tendon-bone graft after anterior cruciate ligament reconstruction: A canine model study. *Am J Sports Med* 2004;32:870-880.
 29. Yamazaki S, Yasuda K, Tomita F, Tohyama H, Minami A. The effect of transforming growth factor-1 on intraosseous healing of flexor tendon autograft replacement of ACL in dogs. *Arthroscopy* 2005;21:1034-1041.
 30. Steiner ME, Murray MM, Rodeo SA. Strategies to improve anterior cruciate ligament healing and graft placement. *Am J Sports Med* 2008;36:176-189.
 31. Orrego M, Larrain C, Rosales J, et al. Effects of platelet concentrate and bone plug on the healing of hamstring tendons in bone tunnel. *Arthroscopy* 2008;24:1373-1380.
 32. de Mos M, van der Windt A, Jahr H, et al. Can platelet-rich plasma enhance tendon repair? A cell culture study. *Am J Sports Med* 2008;36:1171-1178.
 33. Radice F, Yañez R, Gutiérrez V, Pinedo M. Application of platelet-derived growth factors in ACL reconstruction. Practical advice to quantify dosage and to avoid its loss when passing through the bone tunnels. *NotiSLARD* 2007;2:7-8. Available from: www.slard.org.
 34. Radice F. Preparation of the graft in ACL reconstruction, applying platelet-derived growth factors. Video 10. November 2005. Available from: www.socht.cl.
 35. Ju YJ, Tohyama H, Kondo E, et al. Effects of local administration of vascular endothelial growth factor on properties of the in situ frozen thawed anterior cruciate ligament in rabbits. *Am J Sports Med* 2006;34:84-91.
 36. Yoshikawa T, Tohyama H, Katsura T, et al. Effects of local administration of vascular endothelial growth factor on mechanical characteristics of the semitendinosus tendon graft after anterior cruciate ligament reconstruction in sheep. *Am J Sports Med* 2006;36:1918-1925.