

Rapid Healing and Reduced Erythema after Ablative Fractional Carbon Dioxide Laser Resurfacing Combined with the Application of Autologous Platelet-Rich Plasma

JUNG-IM NA, MD, JEE-WOONG CHOI, MD, HYE-RYUNG CHOI, PHD, JEONG-BOK JEONG, MSC, KYOUNG-CHAN PARK, MD, PHD, SANG-WOONG YOUN, MD, PHD, AND CHANG-HUN HUH, MD, PHD*

BACKGROUND Fractional carbon dioxide laser resurfacing (FxCr) has shown considerable efficacy in reducing wrinkles, although complications such as scarring and prolonged erythema are more common and down-time is longer than with nonablative laser treatment. Platelet-rich plasma (PRP), a high concentration of platelets in a small volume of plasma, is known to enhance tissue healing.

OBJECTIVE To evaluate the benefits of PRP in the wound healing process after FxCr.

MATERIALS AND METHODS Twenty-five subjects were treated with FxCr on the bilateral inner arms. PRP was prepared from 10 mL of whole blood and applied on a randomly allocated side, with normal saline being used as the contralateral control. Transepidermal water loss (TEWL) and skin color were measured on both sides. Skin biopsies were also taken from five subjects on day 28.

RESULTS Significantly faster recovery of TEWL was seen on the PRP-treated side. The erythema index and melanin index on the PRP-treated side were lower than on the control side. Biopsy specimens from the PRP-treated side showed thicker collagen bundles than those from the control side.

CONCLUSION Application of autologous PRP is an effective method for enhancing wound healing and reducing transient adverse effects after FxCr treatment.

The authors have indicated no significant interest with commercial supporters.

The introduction of fractional thermolysis revolutionized laser surgery, and this concept is now widely applied to various laser devices. Using a nonablative erbium-doped 1,550-nm laser, the creation of microcolumns of coagulation has been reported, leaving untreated skin between the treated columns. Because epidermal integrity is preserved, and healthy tissue surrounds each wound, healing is much more rapid than with conventional laser resurfacing.¹⁻³ The same concept has been applied in ablative fractional resurfacing with a carbon dioxide (CO₂) wavelength of 10,600 nm. CO₂ devices heat tissue much more intensely than nonablative fractionated devices, ablating epidermal and dermal tissue with significant heating of the immediately adjacent dermal collagen. This collateral heating causes thermal alterations in the helical structure of the col-

lagen fibrils and results in tissue shrinkage⁴ followed by collagen remodeling and skin tightening. In contrast to nonablative fractional laser devices, fractional CO₂ laser resurfacing (FxCr) leaves tiny holes made by vaporization of tissue; tightening is also achieved by collapse of the small vaporized columns.⁵ This effect can be obtained only using ablative fractionated devices, but complications such as postinflammatory hyperpigmentation, prolonged erythema, and scarring are more common in FxCr, and down-time is longer than with nonablative laser treatment.^{1,6}

Platelet-rich plasma (PRP) is a high concentration of platelets in a small volume of plasma. PRP contains various growth factors and cytokines released by platelets, and those substances play a critical role in all aspects of the wound healing process. The wound

*All authors are affiliated with Department of Dermatology, Seoul National University Bundang Hospital, Gyeonggi-do, Korea

healing effect of PRP is relatively well known, and PRP has been used in bone surgery, tendon and ligament repair, and chronic leg ulcer treatment.⁷

The small vaporized holes made using FxCR could be used as a drug delivery route. In this study, we applied PRP on the fractional CO₂ laser-treated site and evaluated the benefits of PRP in the wound healing process after FxCR.

Materials and Methods

Twenty-five subjects were enrolled in the study. Subjects with skin lesions on the inner arms or any bleeding tendency were excluded. The Institutional Review Board of the Seoul National University Bundang Hospital approved the study, and all subjects gave written informed consent. The bilateral inner arms were treated using a fractional CO₂ laser (eCO₂, Lutronic, Seoul, Korea). Each side was irradiated at (10 and 20 mJ) with the same spot density (150/cm²), giving a total of four treatment sites over both arms. The area of each treatment site was 1 cm².

PRP was prepared from autologous blood as previously described.⁸ Ten mL of venous blood was drawn in a syringe prefilled with 1.5 mL of anti-coagulant solution (anticoagulant citrate dextrose solution formula A, Baxter, Deerfield, IL). The blood was centrifuged at 160 g for 10 minutes. After the first spin, the lower red blood cell portion was discarded, and the supernatant was centrifuged at 400 g for 10 minutes. The resulting pellet of platelets was mixed with 1.5 mL of supernatant, which made 1.5 mL of PRP. One mL of 3% calcium chloride was added to the PRP to induce platelet activation.

Activated PRP was applied to the FxCR sites of one randomly assigned arm, and normal saline was applied to the other arm. Laser-treated sites were not dressed, and subjects were instructed to keep the treated sites dry on the day of procedure. Transepidermal water loss (TEWL) was evaluated using a Tewameter (Courage & Khazaka, Cologne, Germany) on both sides. Skin color was measured using

a Mexameter (Courage & Khazaka), which emits light at three defined wavelengths of 568 nm (green), 660 nm (red), and 880 nm (infrared). The erythema index, which indicates the intensity of erythema, is automatically computed from the absorbed and reflected light intensities of the green and red light. The melanin index indicates the darkness of skin and is computed from the absorbed and reflected light intensities of the red and the infrared light.⁹ Clinical photographs were taken on days 0, 1, 3, 7, 14, and 21 (× 60 magnification; Folliscope, Lead M, Seoul, Korea). The results were analyzed using the paired *t*-test using SPSS 15.0 software (SPSS, Inc., Chicago, IL). For histological analysis, biopsy samples were taken from both arms of five subjects on day 28.

Results

Four data groups were compared: FxCR 10 mJ with PRP (T1), FxCR 10 mJ with normal saline (C1), FxCR 20 mJ with PRP (T2), and FxCR 20 mJ with normal saline (C2). The average baseline parameters showed no statistically significant difference between the groups.

TEWL reached its highest level 1 day after irradiation and then rapidly decreased to nearly baseline at day 3 (Figure 1). A slight re-increase in TEWL was observed at approximately day 14; then TEWL decreased again at day 21. This transient re-increase in TEWL was thought to be caused by exfoliation of the crust. All four groups showed a similar TEWL change pattern. The peak TEWL level at day 1 was dependent on microbeam energy. The mean TEWL of the sites treated with 20 mJ was approximately 20% higher than that of the sites treated with 10 mJ. In all subjects, the PRP-treated side showed a greater reduction of TEWL than the control side in the 10-mJ- and 20-mJ-treated sites (Figure 1). Increased levels of TEWL are a sign of impaired barrier function; thus our results showed that PRP treatment induced faster recovery of the skin barrier function.

The intensity of skin redness was measured using the erythema index (EI). During the study, the average

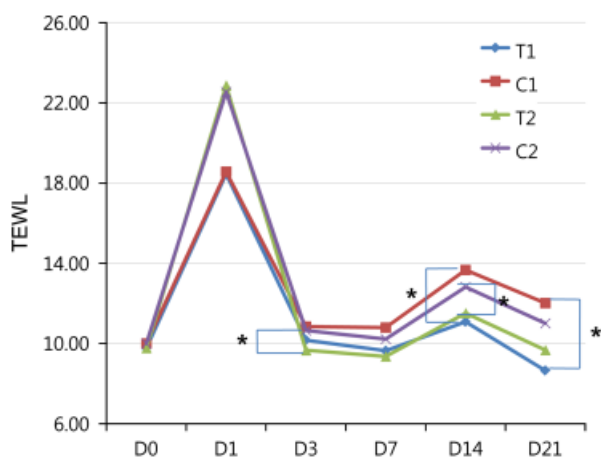


Figure 1. Transepidermal water loss (TEWL) after fractional carbon dioxide (CO₂) laser resurfacing. T1 and T2 are platelet-rich plasma (PRP)-treated sites after a single pass of fractionated CO₂ laser energy of 10 and 20 mJ, respectively. C1 and C2 are the saline-applied control sites after single passes of 10 and 20 mJ, respectively. Peak TEWL level at day 1 was higher at the 20-mJ-treated sites than at the 10-mJ-treated sites. The PRP-treated side had greater average reduction of TEWL than the control side. D0, before treatment; D1, 1 day after treatment; D3, 3 days after treatment; D7, 7 days after treatment; D14, 14 days after treatment; and D21, 21 days after treatment. * $p < .05$ with the paired t -test.

EI decreased continuously after the peak value at day 1. The PRP-treated side showed a lower EI, which means that it was less erythematous than the control side, and a significant difference was observed at day 1 in the 10-mJ-treated sites ($p < .05$). The 20-mJ-treated sites also showed a higher EI level than the 10-mJ treated sites (Figure 2A), but the difference was not statistically significant.

The melanin index (MI) measures the darkness of the skin and is an indicator of potential postinflammatory hyperpigmentation (PIH). At day 1, the MI temporarily decreased, and then an abrupt increase in the MI was seen between day 1 and day 3, reaching the highest level at day 7 and then decreasing gradually until the end of the study. The PRP-treated side had a lower average MI, meaning a brighter skin color with less PIH, and a statistically significant difference was observed at day 3 between T1 and C1 ($p < .05$); the MI of T2 was also lower than C2, but the difference was not significant (Figure 2B).

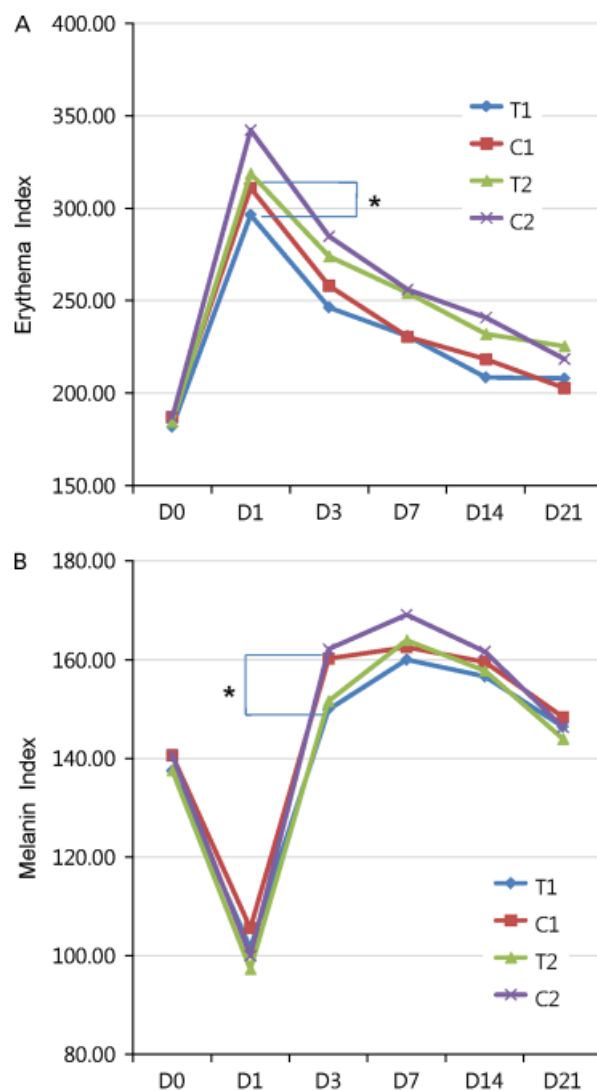


Figure 2. (A) Erythema index (EI) (B) and melanin index (MI) after fractional carbon dioxide (CO₂) laser resurfacing. T1 and T2 are the averaged values of the indices in the platelet-rich plasma (PRP)-treated sites after a single pass of 10 and 20 mJ, respectively. C1 and C2 are the averaged values in the saline applied sites after a single pass of 10 and 20 mJ, respectively. The average EI and MI of the PRP-treated sides were lower than on the control sides, suggesting less erythema and a brighter skin color due to control of transient postinflammatory hyperpigmentation. D0, before treatment; D1, 1 day after treatment; D3, 3 days after treatment; D7, 7 days after treatment; D14, 14 days after treatment; and D21, 21 days after treatment. * $p < .05$ with the paired t -test.

Figure 3 shows representative clinical photography of T2 and C2 areas taken with the Folliscope. The PRP-treated side (T2) shows less erythema and less pigmentation. The crust fell off on day 14, and the control side skin was more scaly than the PRP

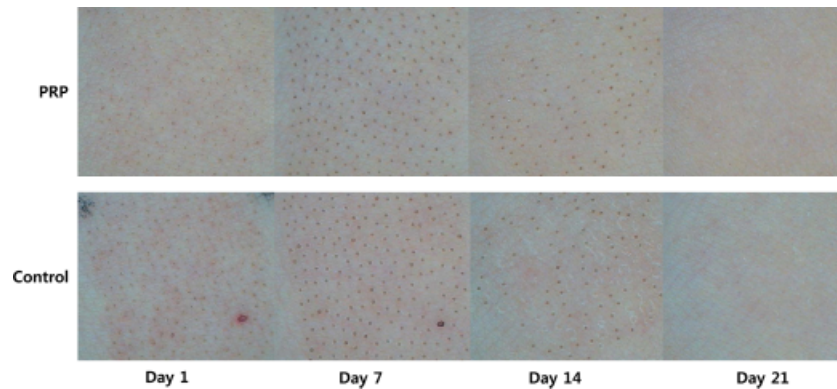


Figure 3. Folliscope images (magnification $\times 60$) of fractional carbon dioxide laser-treated sites. The platelet-rich plasma (PRP)-treated side shows less erythema.

side on day 14. Representative hematoxylin and eosin-stained images of biopsy samples obtained from control and PRP-treated side on postirradiation day 28 are shown in Figure 4. On the PRP-treated side, the epidermis is thicker, and the stratum corneum is better-organized than in the control specimen, and the collagen density is higher, with better organization of the thicker collagen fiber bundles. Adverse effects such as infection, prolonged erythema, and scarring were not observed in either side in any group.

Discussion

Ultrapulse fully ablative CO₂ laser resurfacing is considered to be the most effective treatment for deep facial wrinkles and other aspects of severe photodamage, but even in well-trained hands, full-face laser resurfacing causes prolonged erythema

that can last 6 weeks or longer, and there are risks of permanent hypo- or hyperpigmentation and scarring. FxCR was developed to reduce the complications of conventional CO₂ laser resurfacing while still approaching the superior efficacy of ablative resurfacing. Although it offers very good results and appears to diminish adverse effects significantly, scarring and infection can still occur after FxCR,^{6,10} and down time is longer than with nonablative fractional resurfacing.

In addition to their well-known function in hemostasis, platelets also play a critical role in wound healing. When platelets are activated, they exocytose intracellular granules that contain growth factors such as platelet-derived growth factor (PDGF), transforming growth factor alpha and beta (TGF- α and β), epidermal growth factor, basic fibroblastic growth factor, and vascular endothelial

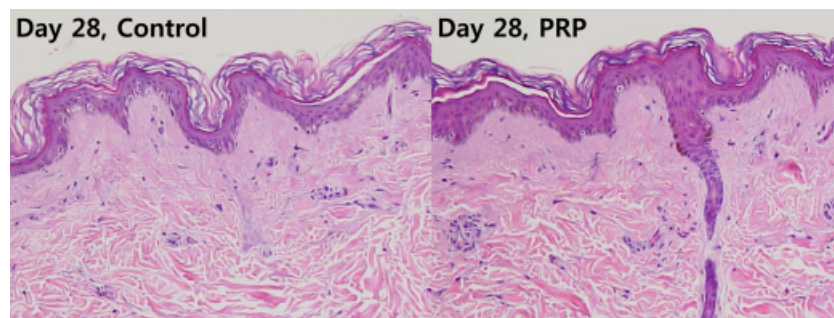


Figure 4. Hematoxylin and eosin stain of biopsy specimen from fractional carbon dioxide laser-treated sites on day 28. A thicker epidermis with a better-organized stratum corneum is observed in the platelet-rich plasma (PRP)-treated side, together with thicker bundles of dermal collagen fibers.

growth factor. Those growth factors stimulate the proliferation of epidermal cells and fibroblasts, promote angiogenesis, and induce collagen synthesis.¹¹ The wound-healing effects of PRP in chronic skin ulcers^{12–14} and acute wounds is well established.^{15,16} The results in the present study demonstrated that faster wound healing after FxCR treatment could also be achieved with the application of PRP.

The PRP-treated side showed less erythema in all subjects. Platelets contain various materials related to angiogenesis and vascular modeling.⁷ With orchestration of these materials, PRP seems to induce the appropriate level of angiogenesis without causing excessive vessel formation. Prolonged erythema is a common complication of FxCR, so combining FxCR with PRP would be a good strategy. PRP also reduced transient pigmentation after FxCR. Incontinentia pigmenti is the most characteristic feature of PIH, which occurs after destruction of the basal cell layer. Melanophages phagocytizing degenerating basal keratinocytes and melanocytes, which contain a large amount of melanin, accumulate in the upper dermis.¹⁷ TGF- β in PRP is known to stimulate secretion of basement membrane protein such as laminin, collagen IV, and tenascin.¹⁸ Faster repair of the basement membrane might reduce incontinentia pigmenti, resulting in less pigmentation after FxCR. TGF- β is also known to decrease melanogenesis.¹⁹ The exact mechanism by which PRP could reduce transient pigmentation remains to be elicited, but it could also be helpful in achieving optimum results in patients undergoing FxCR skin rejuvenation.

In the biopsy specimens taken 4 weeks after the procedure, in other words well into the remodeling stage of wound healing, thicker collagen bundles were observed in specimens from the PRP-treated side. This might be because of the enhanced tissue remodelling effect of PRP. PDGF is a potent mitogen of mesenchymal stem cells.²⁰ PDGF and TGF- β in PRP also promote collagen and other extracellular matrix synthesis. Therefore, PRP might enhance the skin rejuvenation effect of FxCR. Collapse of the small vaporized holes is another of the

immediate skin shrinkage mechanisms associated with FxCR. Activated PRP becomes a gel-like material containing fibrin, and fibrin can be used as biologic glue.^{21,22} Adding biologic glue to the microablative columns produced using FxCR might assist in the collapse of the columns and enhance the shrinkage of redundant wrinkled skin. Further investigation is needed to elucidate the adjunctive effect of, and the balance between, immediate skin shrinkage and collagen remodeling-mediated skin tightening associated with the combination of FxCR and PRP.

In summary, the results of the present study strongly suggest that the application of autologous PRP could be an effective method for enhancing wound healing, reducing transient unwanted adverse effects, and improving skin tightening after FxCR skin rejuvenation.

References

1. Groff WF, Fitzpatrick RE, Uebelhoefer NS. Fractional carbon dioxide laser and plasmakinetic skin resurfacing. *Semin Cutan Med Surg* 2008;27:239–51.
2. Manstein D, Herron GS, Sink RK, et al. Fractional photothermolysis: a new concept for cutaneous remodeling using microscopic patterns of thermal injury. *Lasers Surg Med* 2004;34:426–38.
3. Bedi VP, Chan KF, Sink RK, et al. The effects of pulse energy variations on the dimensions of microscopic thermal treatment zones in nonablative fractional resurfacing. *Lasers Surg Med* 2007;39:145–55.
4. Hantash BM, Bedi VP, Chan KF, et al. Ex vivo histological characterization of a novel ablative fractional resurfacing device. *Lasers Surg Med* 2007;39:87–95.
5. Hantash BM, Bedi VP, Kapadia B, et al. In vivo histological evaluation of a novel ablative fractional resurfacing device. *Lasers Surg Med* 2007;39:96–107.
6. Fife DJ, Fitzpatrick RE, Zachary CB. Complications of fractional CO₂ laser resurfacing: four cases. *Lasers Surg Med* 2009;41:179–84.
7. Anitua E, Andia I, Ardanza B, et al. Autologous platelets as a source of proteins for healing and tissue regeneration. *Thromb Haemost* 2004;91:4–15.
8. Gonshor A. Technique for producing platelet-rich plasma and platelet concentrate: background and process. *Int J Periodontics Restorative Dent* 2002;22:547–57.
9. Park ES, Na JL, Kim SO, et al. Application of a pigment measuring device—Mexameter—for the differential diagnosis of vitiligo and nevus depigmentosus. *Skin Res Technol* 2006;12:298–302.

10. Avram MM, Tope WD, Yu T, et al. Hypertrophic scarring of the neck following ablative fractional carbon dioxide laser resurfacing. *Lasers Surg Med* 2009;41:185–8.
11. Rozman P, Bolta Z. Use of platelet growth factors in treating wounds and soft-tissue injuries. *Acta Dermatovenerol Alp Panonica Adriat* 2007;16:156–65.
12. Tarroni G, Tessarin C, De Silvestro L, et al. [Local therapy with platelet-derived growth factors for chronic diabetic ulcers in haemodialysis patients]. *G Ital Nefrol* 2002;19:630–3.
13. Mazzucco L, Medici D, Serra M, et al. The use of autologous platelet gel to treat difficult-to-heal wounds: a pilot study. *Transfusion* 2004;44:1013–8.
14. Margolis DJ, Kantor J, Santanna J, et al. Effectiveness of platelet releasate for the treatment of diabetic neuropathic foot ulcers. *Diabetes Care* 2001;24:483–8.
15. Everts PA, Devilee RJ, Brown Mahoney C, et al. Platelet gel and fibrin sealant reduce allogeneic blood transfusions in total knee arthroplasty. *Acta Anaesthesiol Scand* 2006;50:593–9.
16. Hom DB, Linzie BM, Huang TC. The healing effects of autologous platelet gel on acute human skin wounds. *Arch Facial Plast Surg* 2007;9:174–83.
17. Lacz NL, Vafaie J, Kihiczak NI, et al. Postinflammatory hyperpigmentation: a common but troubling condition. *Int J Dermatol* 2004;43:362–5.
18. Tamariz-Dominguez E, Castro-Munozledo F, Kuri-Harcuch W. Growth factors and extracellular matrix proteins during wound healing promoted with frozen cultured sheets of human epidermal keratinocytes. *Cell Tissue Res* 2002;307:79–89.
19. Burd A, Zhu N, Poon VK. A study of Q-switched Nd:YAG laser irradiation and paracrine function in human skin cells. *Photodermatol Photoimmunol Photomed* 2005;21:131–7.
20. Blande IS, Bassaneze V, Lavini-Ramos C, et al. Adipose tissue mesenchymal stem cell expansion in animal serum-free medium supplemented with autologous human platelet lysate. *Transfusion* 2009;49:2680–5.
21. Mandel MA. Minimal suture blepharoplasty: closure of incisions with autologous fibrin glue. *Aesthetic Plast Surg* 1992;16:269–72.
22. Chakravorty RC, Sosnowski KM. Autologous fibrin glue in full-thickness skin grafting. *Ann Plast Surg* 1989;23:488–91.

Address correspondence and reprint requests to: Chang-Hun Huh, MD, Department of Dermatology, Seoul National University College of Medicine, Seoul National University Bundang Hospital, 300 Gumi-dong, Bundang-gu, Seongnam-si, Gyeonggi-do 463-707, Korea, or e-mail: chhuh@snu.ac.kr