

Treatment of Achilles Tendinopathy with Platelet-Rich Plasma

Authors

K. Gaweda^{1,2}, M. Tarczynska^{1,2}, W. Krzyzanowski²

Affiliations

¹ Medical University of Lublin, Orthopaedic Surgery, Lublin, Poland

² NZOZ Arthros Orthopaedic Surgery, Naleczow, Poland

Key words

- non-insertional achilles tendinopathy
- autologous platelet-rich plasma
- ultrasonography
- power-doppler ultrasonography

Abstract

▼
Non-insertional Achilles tendinopathy commonly impedes the functioning of active persons. Treatment methods vary, as do their results. The aim of the study was to evaluate the effectiveness of non-insertional Achilles tendinopathy treatment with autologous platelet-rich plasma (PRP). Autologous PRP was injected into the affected Achilles tendon of 14 prospectively selected patients (15 Achilles tendons). Before PRP administration, all patients were evaluated using the American Orthopedic Foot and Ankle Society (AOFAS) scale for the hind foot, and the Victorian Institute of Sport Assessment – Achilles (VISA-A) scale. Ultrasonography (US) and Power-

Doppler ultrasonography (PDUS) of the area was also performed. Identical physical and imaging evaluations were performed at 6 weeks, and at 3, 6, and 18 months after injection. During follow up, a significant improvement was observed in the clinical and imaging results. The AOFAS scale improved from a baseline median of 55 points to 96 points at 18 months ($p=0.000655$), while the VISA-A scale improved from a baseline of 24 to 96 ($p=0.000655$) in the final evaluations. During the final evaluation, one subject experienced minor pain following prolonged daily activity, while another subject complained of pain following overloading activity. Local, accurate PRP administration improved symptoms of non-insertional Achilles tendinopathy.

Introduction

▼
As a rule, performance impairment in active subjects connected with pain in the posterior surface of the distal calf and heel area is related to various Achilles tendon pathology syndromes [15]. The location and character of pathological lesions vary [28]. The aetiology of the condition is most frequently associated with overload in middle-aged subjects [4]. Pathological processes rarely develop at the Achilles tendon attachment to the calcaneus (i.e., insertional tendinopathy), and are frequently localized 2–6cm above the tendon-bone junction (i.e., non-insertional tendinopathy) [19]. The incomplete understanding of the variable nature of pathological lesions observed in the course of these processes has led to persistent controversy over treatment methods and even nomenclature [6,23]. The initial collective designation of all pain syndromes of the area as calcaneal tendon inflammation (Achilles tendinitis) proved to be erroneous [23]. Inflammatory lesions are rarely seen in clinical, imaging, and histological examinations [3,12].

These most frequently involve the peritendineum [12] and are frequently asymptomatic [23]. Lesions involving fatty or mucinoid degeneration within the peripheral section of the Achilles tendon proved to be the cause of complaints [23]. The term ‘tendinitis’, pointing to an inflammatory aetiology, is not proper for these lesions, and has been replaced by the terms of tendinosis or tendinopathy [23]. For many years, the belief of an inflammatory aetiology has caused systemic and topical anti-inflammatory treatment to be the principal therapy. Since this treatment frequently proved to be ineffective, other solutions needed to be sought, both surgical and non-surgical [13, 14, 26]. Nevertheless, it remains unclear, which of the suggested treatments is more effective [8, 21]. First reports of treatment opportunities with platelet-rich plasma (PRP), presented in recent publications, are also encouraging [11, 16, 22]. PRP contains high levels of growth factors, and their activity may have a potential impact on tendon healing.

The objective of the study was to evaluate the effectiveness of the treatment of non-insertional

accepted after revision
May 04, 2010

Bibliography

DOI <http://dx.doi.org/10.1055/s-0030-1255028>
Published online: 2010
Int J Sports Med
© Georg Thieme Verlag KG
Stuttgart · New York
ISSN 0172-4622

Correspondence

Dr. Krzysztof Gaweda
Medical University of Lublin
Orthopaedic Surgery
Jaczewskiego 8
20-954 Lublin
Poland
Tel.: +48/81/72 44 510
Fax: +48/81/72 44 511
krzylub@o2.pl

tendinopathy of the Achilles tendon with localised injections of autologous platelet-rich plasma.

Material and Methods

Fourteen subjects (6 women and 8 men), aged 24–52 years (average 40 years), were treated. In one subject, lesions involved both calcaneal tendons. Therefore, 15 tendons were treated. Sports or physical activities with excessive load were reported in five cases. Diabetes mellitus-related metabolic disorders were seen in one subject. The period of impaired performance preceding treatment with autologous PRP was between 3 and 10 months (6 months on average). PRP injections were applied following failure of all other treatment modalities. Plaster cast immobilisation was initially used in eight patients; ten subjects underwent various physiotherapeutic procedures. Four patients received single steroid injections. As seen above, some patients received several therapies. None of the previously used treatments alleviated the tendinopathy symptoms. In all cases, the interval between previous treatments and PRP injections exceeded 3 months. All subjects were tracked for at least 18 months following PRP treatment.

Patients were randomly chosen from among those seeking treatment at the hospital out-patient clinic. Based on preliminary subjective and objective examinations, subjects with symptoms of non-insertional tendinopathy were selected. All patients suffered from painful thickening of the Achilles tendon region, at least 2 cm above its junction with the calcaneus. Plantar and dorsal flexion was pain limited. Preserved pronation and supination in the subtalar joint resulted in pain in the peripheral section of the Achilles tendon. Patients with symptoms of insertional tendinopathy were excluded from further assessments. Objective function assessment was performed using the American Orthopedic Foot and Ankle Society (AOFAS) scale for the hind foot, and the Victorian Institute of Sport Assessment – Achilles (VISA-A) scale [9,20]. Radiographs of the ankle joint with distal half of the calf were taken in all patients in standard projections. If the images did not reveal radiological lesions in the skeletal system, the calcaneal tendon painful section was examined using an ultrasound (US) 12–15 MHz linear probe. Sonographic evaluation included verification of the continuity of the entire tendon, as well as its inner structure. We searched for tendon homogeneity disruption and occurrence of hypoechoic foci, as well as presence or absence of tendon and peritendineum thickening. The presence of markedly decreased echogenicity areas within the tendon, with loss of normal fibrillar pattern, was recorded as intrasubstance tears. All other areas of decreased echogenicity were classified generally as hypoechoic foci. (◉ **Fig. 1**) US does not provide the ability to clearly differentiate the nature of the observed lesions [2,18]. Tendon movement was evaluated in a dynamic examination upon active and passive dorsal and plantar flexion of the foot, with fixed US probe positioning above the lesion, so as to rule out tendon adhesions with neighbouring tissues. Total tendon shift range was not quantitatively assessed. Power-Doppler ultrasonography (PDUS) was used to assess vascular flow intensity in the tendon and surrounding tissues, in both longitudinal and transverse planes. Pulse repetition frequency (PRF) was set and maintained at 1.25 kHz for all assessments. Power-Doppler sensitivity was adjusted until no colour signal was present down to the bone cortex. Standard hematological and biochemical tests were con-

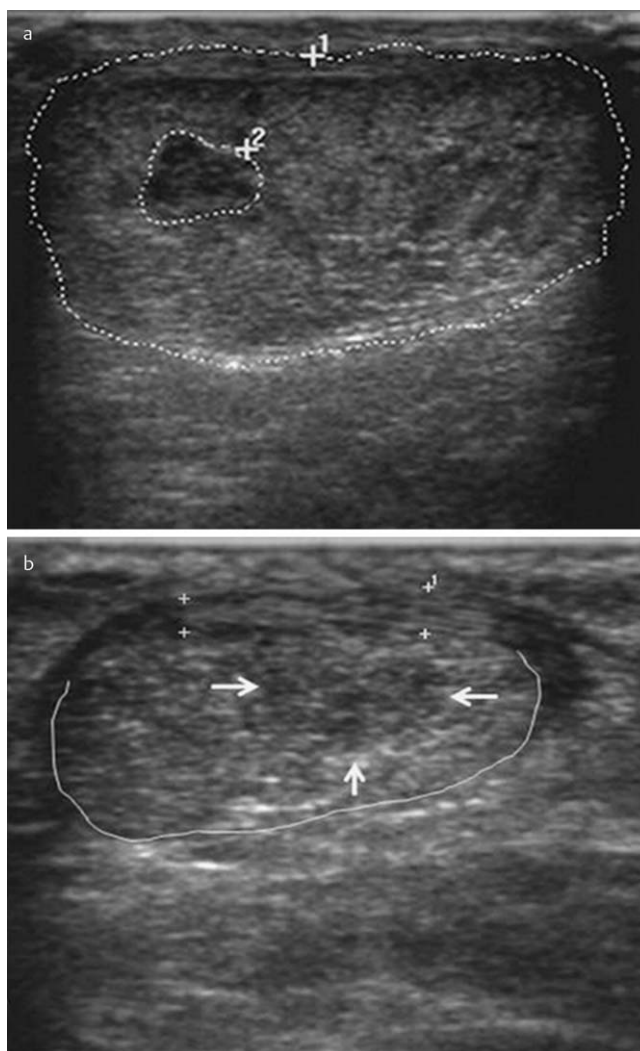


Fig. 1 Transverse US view of Achilles tendinopathy. **a** Within the heterogeneous and thickened tendon (rim 1), an intrasubstance tear (rim 2) is evidenced. **b** Thickened peritendineum (between '+' marks) and irregular hypoechoic lesions (arrows) within the tendon (rim).

ducted to exclude systemic inflammatory symptoms, i.e. blood cell count with leucocytosis, sedimentation rate and C-reactive protein level. After providing informed consent, subjects meeting all diagnostic criteria were included in the treatment group. Peripheral blood was taken from all patients, and a platelet-rich suspension was prepared according to the recommendations of the manufacturer of the separator (PRP Kit, Curasan) [27]. Under US control, an average volume of 3 ml PRP was injected into the hypoechoic areas of affected tendons. Patients were advised to avoid full loading of the limb, to use elbow crutches, and to elevate the limb for 3 days after injection. In the next 2 weeks, patients used walking crutches with pressure applied on the anterior section of the foot, and passively exercised the ankle joint. For the subsequent 2 weeks, the load on the foot was increased using a heel lift in the patient's own shoes; passive exercises and active exercises without load were continued. Six weeks after injection, full load without crutches began. Rehabilitation procedures were selected, in conformance with previous experience with a group of patients with Achilles rupture. Heel lifts were still being used. At that time, all patients underwent repeated assessment of their feet using AOFAS and VISA-A

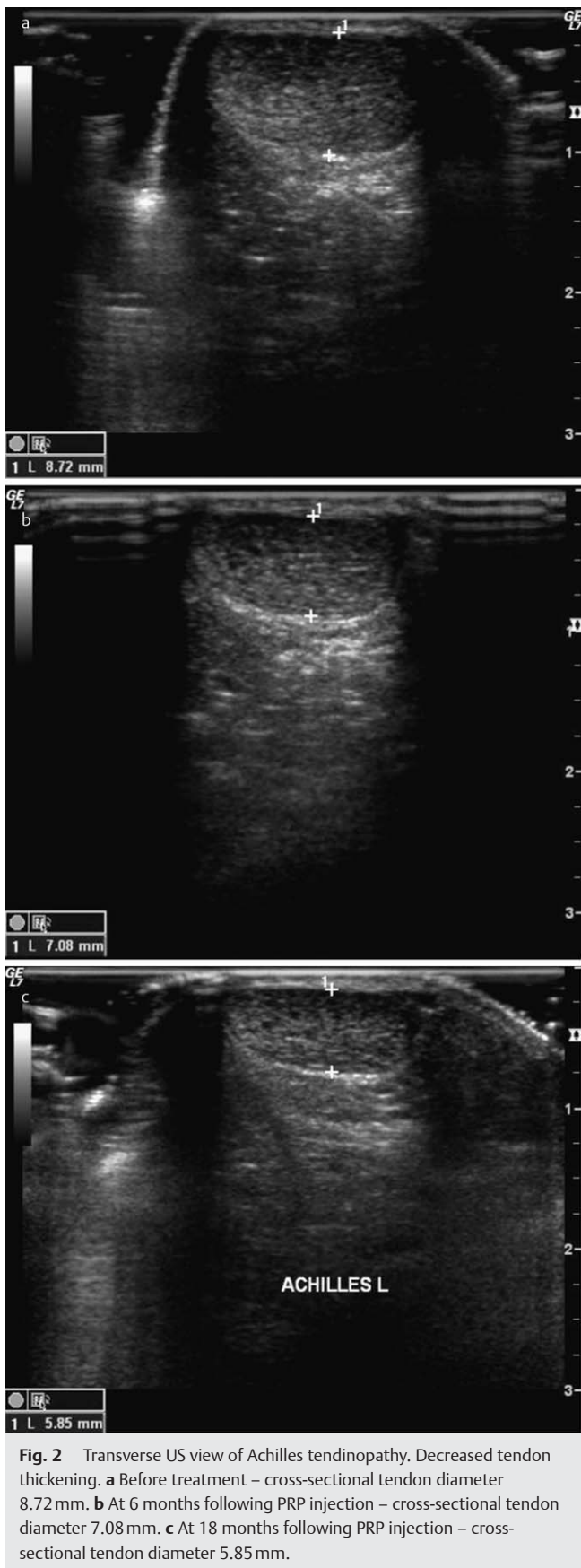

Fig. 2 Transverse US view of Achilles tendinopathy. Decreased tendon thickening. **a** Before treatment – cross-sectional tendon diameter 8.72 mm. **b** At 6 months following PRP injection – cross-sectional tendon diameter 7.08 mm. **c** At 18 months following PRP injection – cross-sectional tendon diameter 5.85 mm.

scales, according to the criteria used for the baseline assessment. US and PDUS assessments were also performed. The same features evaluated at baseline were re-evaluated. Signs indicating tendon healing were sought. These included size reduction or regression of hypoechogenic foci, more homogeneous tendon echographic structure, as compared with previous images, appearance of a fibrillar pattern within the previously affected tendon section, if not present at baseline, and reduced maximum thickness of tendon. (► **Fig. 2**) Normal daily activity was recommended once signs of tendon healing were observed. A temporary heel lift was still being used. Patients were discouraged to engage in sport activities, including recreational level. In six cases, persistent symptoms and unclear signs of tendon healing on US were observed, and the injection was repeated. Patients who did not require repeated injections gradually resumed normal activities between the 6th and 12th week after the injection. Patients receiving repeated injections were gradually mobilized just as after the first injection. In all cases, clinical assessments using functional evaluation scales, US and PDUS were conducted at 6 weeks, and at 3, 6, and 18 months. With the use of Shapiro-Wilk test we concluded that distribution of some variables significantly differ from normal. On the basis of this conclusion for repeated measurements analysis we used non-parametric Friedman ANOVA test and non-parametric Wilcoxon test for analysis of differences between each time point. Results are shown as median and minimum and maximum values.

The study was conducted in conformance with the ethical standards of the International Journal of Sports Medicine and approved by the Bioethics Commission, according to principles of Good Clinical Practice [7].

Results



Before treatment administration, the median for the AOFAS functional score for the posterior part of the foot was 55 points (range 36–72). For the VISA-A scale, the median was 24 points (range 8–31). In US assessment, all subjects had evidence of fusiform tendon thickening, and six subjects also showed peritendineum thickening within the painful section. In 11 cases, loose disruption of cross-sectional diameter was observed in the area of tendon fibres. Numerous small intrasubstance tendon tears were seen in three cases, and a few were also observed in eight other cases. All 11 of these patients had marked hypoechogenic lesions within this area; limited lesions were observed in the four remaining cases. At dynamic examination, substantial tendon mobility limitation was reported in three patients; two had marked hypoechogenic lesions within the tendon, possibly evidence of intrasubstance hyalinisation. These patients had previously received local steroid injections into the affected areas. No inflammatory reactions were seen in the retrocalcaneal bursa in any of the subjects. In one patient, PDUS assessment showed evidence of increased blood flow within the affected areas.

We noticed statistically significant ($p < 0.0005$ in non-parametric Friedman ANOVA test) increase in both scores during observation period. At 6 weeks, the AOFAS score median was 72 points (range 64–84), and the VISA-A score median was 44 points (range 27–51). In US assessment, tendon thickening within the intrasubstance tendon tears was observed in two patients, as compared with baseline. Tendon thickness remained unchanged among remaining patients. Peritendineum thickness was

	Initial	6 weeks	3 months	6 months	18 months
VISA-A	24 (8–31)	44 (27–51)	66 (49–87)	92 (65–98)	96 (80–100)
AOFAS	55 (36–72)	72 (64–84)	84 (71–97)	96 (76–100)	96 (82–100)

Table 1 The median (range) functional scores of the VISA-A and AOFAS.

Table 2 The results of the US and PDUS examinations.

Number of cases	Initial	6 weeks	3 months	6 months	18 months
fusiform tendon thickening	15	13	4	2	1
peritendineum thickening	6	6	6	2	2
hypoechoic foci	15	15	11	2	1
intrasubstance tendon tears	11	11	4	1	–
tendon gliding limitation	3	3	1	–	–
vascular impulses – tendon	1	13	15	8	2
vascular impulses – peritendineum and surrounding	1	13	15	12	12

unchanged, compared to baseline assessments. A discrete size reduction of hypoechoic lesions was observed. Compared with baseline, tendon mobility did not change. In 13 cases, increased vasculature was observed within the tendon, the peritendineum, and anterior to it, compared to baseline assessments.

At 3 months, the AOFAS score median was 84 points (range 71–97), while the median VISA-A score was 66 (range 49–87). There was a statistically significant score increase of both scales ($p < 0.0005$). In US evaluation, regression of fusiform tendon thickening was observed in 11 cases. No differences in peritendineum thickness were noted, when compared with the 6 weeks assessment. Previously reported focal areas without fibrillar pattern resolved in seven cases, whereas four tendons showed minimal residual fibrillar discontinuity. Cross-sectional diameter of the tendon was increased in areas with previously observed fibrillar disruption. Residual hypoechoic foci were reported. There were no more hypoechoic areas in four subjects. On PDUS assessment, vascular activity increased in the tendon and surrounding areas, and was observed in all 15 tendon bodies, as well as anterior to the tendon.

At 6 months, the AOFAS score median was 96 points (range 76–100). The VISA-A score median was 92 points (range 65–98 points). The value differences of the employed functional scales in comparison with the initial examination were statistically significant ($p < 0.0005$). Thirteen patients had no local pain or thickening of the Achilles tendon, whereas two subjects complained of local pain and thickening. On US assessment, all the tendons were thinner, although still thicker than normal in the two subjects with persistent clinical symptoms. The peritendineum thickening was reduced, except in these two cases. A few hypoechoic lesions were observed within the tendon in the same two subjects. One patient still showed evidence of a small area of tendon discontinuity. All patients had normal, symmetric Achilles tendon mobility. Vascular flows were observed within the tendon in eight cases, and anterior to the tendon in twelve cases.

Eighteen months after PRP treatment, the median of AOFAS score was 96 points (range 82–100). The median of VISA-A score was 96 points (range 80–100). In this observation period the differences of the point value in both scales were statistically significant ($p < 0.0005$). The same two patients still suffered functional limitations due to pain in the Achilles region, although pain was markedly reduced in both subjects, when compared to the 6 months evaluation: one patient had pain during recreational sport activity and was pain-free during usual daily activi-

ties; the second subject was pain-free at rest, but had pain on walking a short distance. In US assessment, tendon thickening was seen in one patient and peritendineum thickening was present in both cases with pain. Hypoechoic foci were observed in one case only. No intrasubstance tears were seen. In all cases, tendon movement was not limited. In PDUS assessments, vascular flows were still present in the two painful tendons. These two patients also showed evidence of vascular activity anterior to the tendon. Surprisingly, ten clinically healthy tendons have also shown evidence of vascular activity anterior to the tendon. The number of vascular signals in the clinically healthy tendons was significantly inferior, when compared to the assessment at 6 months.

Analysis of repeated measurements shown that AOFAS and VISA-A scores increased significantly during observation period ($p < 0.001$). A statistical analysis of AOFAS and VISA-A scores in each observation period demonstrated very highly significant improvements, when compared with baseline values ($p \leq 0.001$; **Table 1**). US and PDUS parameters at follow-up are summarised in **Table 2**.

Longitudinal and transverse US and PDUS images of Achilles tendinopathy for each follow-up period are presented in **Fig. 3, 4**.

Discussion



Prior to PRP injections, the eccentric exercises recommended by Woodley *et al.* [29] and Fahlstrom *et al.* [5] did not provide improvement in our subjects. The average duration of eccentric exercise was 7 months, with a range of 5–10 months. Based on a review of 607 papers, Rompe *et al.* assessed the value of non-steroidal anti-inflammatory drug (NSAID) administration, steroid injections, the use of heel lifts, and diverse forms of physiotherapy for the treatment of Achilles tendinopathy [21]. They concluded that the usefulness of these interventions was comparable to placebo effect, and the results were comparable to those achieved in patient groups without any treatment. Surgical solutions proposed by Schepesis *et al.* were not assessed, and we did not perform surgical treatment [23]. Similarly, we were unable to assess the effectiveness of endoscopic procedures recommended by Steenstra and van Dijk [25].

The treatment of chronic non-insertional tendinopathy of the calcaneal tendon with PRP injections achieved resolution of acute symptoms in all of our patients, confirming reports by other authors, who suggested improvement of regenerative abil-

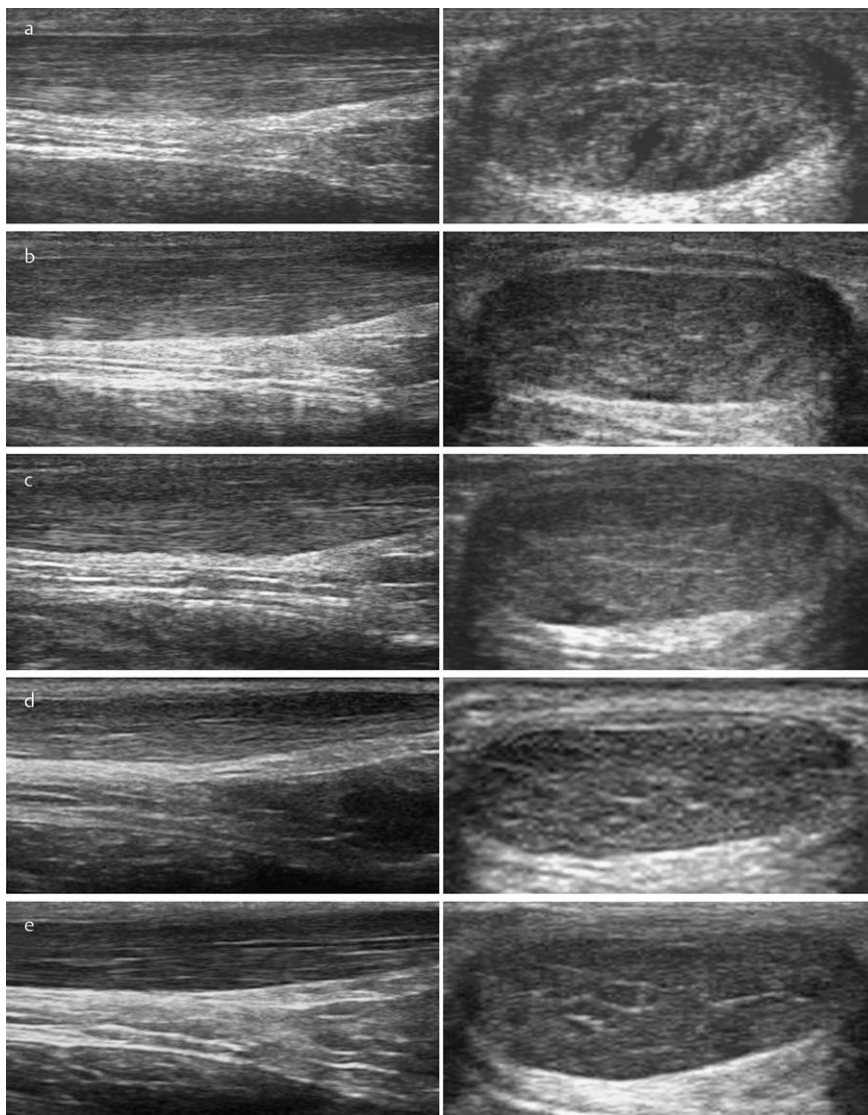


Fig. 3 The longitudinal and transverse US images.

- a** initial longitudinal and transverse.
- b** longitudinal and transverse at 6 weeks.
- c** longitudinal and transverse at 3 months.
- d** longitudinal and transverse at 6 months.
- e** longitudinal and transverse at 18 months.

ities of tendons following local administration of growth factors. Kurtz *et al.* [11] presented the anti-inflammatory effect of insulin-like growth factor (IGF1) in sectioned tendon healing, and Sanchez *et al.* [22] reported a similar effect after administering preparations rich in growth factors (PRGF). Studies on sheep, performed by Anitua *et al.*, showed that blood platelet concentrates administered on fibrin matrices accelerated and modelled the multiplication of active tendon cells and stimulated neovascularisation [1]. Neovascularisation has been previously assumed to be a relatively specific sign for painful tendon [17], though some symptomatic patients did not show evidence of vascular signals [30]. In our study, increased tendon vascularisation at follow-up was observed in all subjects, whereas symptoms gradually diminished in most of them. This finding contradicts results presented by Ohberg *et al.* [17] These closely associate neovascularisation with chronic achillodynia. We were unable to clearly explain this phenomenon. The increased vascularisation seen within the tendon in PDUS assessments during treatment was probably associated not only with recruitment of new vessels, but also with increased blood flow into the tendon. Research performed by Schnabel *et al.* on horse tendon models indicate that increased blood platelet concentration and the related release of growth factors increased the expression of genes involved in tendon reconstruction [24]. Mishra and Pavelko

investigated treatment of tendinopathy of wrist and finger extensor tendon insertion in the lateral humeral epicondyle area, using buffered platelet-rich plasma and achieved encouraging results [16]. In the present study, PDUS assessment yielded puzzling results. At baseline, there were no vascular signals in 14 tendons, with limited vascularisation in 1 tendon. During follow-up assessments at 6 weeks and at 3 months, the number of vascular signals in the affected tendon and anterior surrounding soft tissues increased. This picture changed in the assessment at 6 months; the number of vessels in the tendon body decreased, whereas to a more limited extent in the anterior region. Nevertheless, vascular activity was seen in 12 cases. At the final follow-up assessment at 18 months, PDUS microcirculation signals in the tendon body were absent in 13 cases. Vascular signals in the surrounding tissues were still present, albeit at a reduced level, in 12 patients. Only two patients still complained of pain. Knobloch *et al.* claim that microcirculation disorders may be the cause of tendinopathy [10]. The authors believe that post-capillary congestion is a characteristic feature of this process; it does not, however, influence the tissue oxygenation level. In the present study, the elimination of clinical symptoms, normalization of tendon thickness in the area of intrasubstance tears, decreased peritendineum and tendon thickening, and resolution of hypoechoic lesions observed on US assessment give a pic-

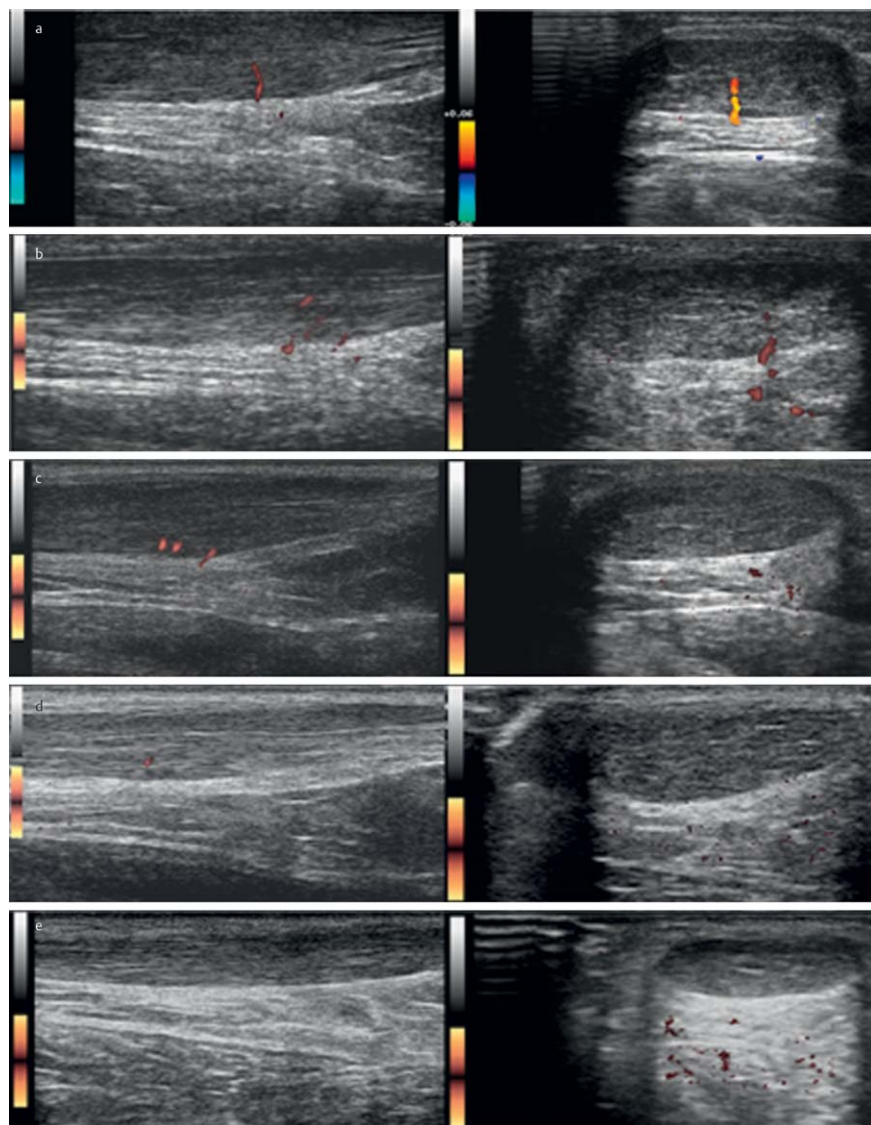


Fig. 4 The longitudinal and transverse PDUS images.

- a** initial longitudinal and transverse.
b longitudinal and transverse at 6 weeks.
c longitudinal and transverse at 3 months.
d longitudinal and transverse at 6 months.
e longitudinal and transverse at 18 months.

ture of high reconstructive effectiveness in Achilles tendinopathy following local injection of autologous PRP. At 18 months, presence of vascular signals anterior to the tendon in clinically healthy patients was observed, with no such activity in the tendon alone. We were unable to clearly explain this very interesting observation. Using contrast-enhanced ultrasonography would have probably provided more information on tendon and surrounding tissues vascularization in these patients. Vascular activity following PRP injection into the affected tendon demonstrated its reparative and long-lasting effect. Direct administration of PRP into the tendon body causes increased vascular activity in the anterior area, which may reflect the involvement of surrounding tissues in tendon healing. A significant improvement of functional evaluation scores with simultaneous lack of complications suggests a substantial value of this treatment. The weight of the study is reduced due to the lack of a control group. As compared with previous treatment modalities, the very high patient satisfaction and achieved activity improvement objectives are encouraging.

Conclusions

▼
 Local administration of autologous platelet-rich plasma in non-insertional tendinopathy of the Achilles tendon markedly reduced or eliminated clinical symptoms. This promising treatment requires further evaluation. The mechanism of the reconstructive processes is not clear, and further studies are necessary.

References

- 1 Anitua E, Sanchez M, Zalduendo M, de la Fuente M, Orive G, Azofra J, Andia I. Autologous fibrin matrices: a potential source of biological mediators that modulate tendon cell activities. *J Biomed Mater Res A* 2006; 77: 285–293
- 2 Åstrom M, Gentz CF, Nilsson P, Rausing A, Sjoberg S, Westlin N. Imaging in chronic Achilles tendinopathy: a comparison of ultrasonography, magnetic resonance imaging and surgical findings in 27 histologically verified cases. *Skeletal Radiol* 1996; 25: 615–620
- 3 Clancy WG Jr. Tendon Trauma and Overuse Injuries in Sports-Induced Inflammation: Clinical and Basic Science Concepts. Chicago, AAOS 1989
- 4 Clement DB, Taunton JE, Smart GW, McNicol KL. A survey of overuse running injuries. *Physician Sportsmed* 1981; 9: 47–58
- 5 Fahlstrom M, Jonsson P, Lorentzon R, Alfredson H. Chronic Achilles tendon treated with eccentric calf-muscle training. *Knee Surg Sports Traumatol Arthrosc* 2003; 11: 327–333

- 6 Fox JM, Blazina ME, Jobe FW, Kerlan RK, Carter VS, Shields CL Jr, Carlson GJ. Degeneration and rupture of the Achilles tendon. *Clin Orthop* 1975; 107: 221–224
- 7 Harriss DJ, Atkinson G. International Journal of Sports Medicine – Ethical Standards in Sport and Exercise Science Research. *Int J Sports Med* 2009; 30: 701–702
- 8 Kader D, Saxena A, Movin T, Maffulli N. Achilles tendinopathy: some aspects of basic science and clinical management. *Br J Sports Med* 2002; 36: 239–249
- 9 Kitaoka HB, Alexander JJ, Adelaar RS, Nunley JA, Mark S, Myerson MS, Sanders M. Clinical rating system for the ankle-hindfoot, midfoot, hallux and lesser toes. *Foot and Ankle International* 1994; 15: 349–353
- 10 Knobloch K, Kraemer R, Lichtenberg A, Jagodzinski M, Gossling T, Richter M, Zeichen J, Hufner T, Krettek C. Achilles tendon and paratendon microcirculation in midportion and insertional tendinopathy in athletes. *Am J Sports Med* 2006; 34: 92–97
- 11 Kurtz CA, Loebig TG, Anderson DD, DeMeo PJ, Campbell PG. Insulin-like growth factor 1 accelerates functional recovery from Achilles tendon injury in a rat model. *Am J Sports Med* 1999; 27: 363–369
- 12 Leach RE, James S, Wasilewski S. Achilles tendinitis. *Am J Sports Med* 1981; 9: 93–98
- 13 Luscombe KL, Sharma P, Maffulli N. Achilles tendinopathy. *Trauma* 2003; 5: 215–225
- 14 Maffulli N, Testa V, Capasso G, Bifulco G, Binfield PM. Results of percutaneous longitudinal tenotomy for Achilles tendinopathy in middle- and long-distance runners. *Am J Sports Med* 1997; 25: 835–840
- 15 Mahieu NN, Witvrouw E, Stevens V, Van Tiggelen D, Roget P. Intrinsic risk factors for the development of Achilles tendon overuse injury: A prospective study. *Am J Sports Med* 2006; 34: 226–235
- 16 Mishra A, Pavelko T. Treatment of chronic elbow tendinosis with buffered platelet-rich plasma. *Am J Sports Med* 2006; 34: 1774–1778
- 17 Ohberg L, Lorentzon R, Alfredson H. Neovascularisation in Achilles tendons with painful tendinosis but not in normal tendons: an ultrasonographic investigation. *Knee Surg Sports Traumatol Arthrosc* 2001; 9: 233–238
- 18 Paavola M, Paakkala T, Kannus P, Jarvinen M. Ultrasonography in the differential diagnosis of Achilles tendon injuries and related disorders. *Acta Radiol* 1998; 39: 612–619
- 19 Puddu G, Ippolito E, Postacchini F. Classification of Achilles tendon disease. *Am J Sports Med* 1976; 4: 145–150
- 20 Robinson JM, Cook JL, Purdam C, Visentini PJ, Ross J, Maffulli N, Taunton JE, Khan KM. The VISA – A Questionnaire: A valid and reliable index of the clinical severity of Achilles tendinopathy. *Br J Sports Med* 2001; 35: 335–341
- 21 Rompe JD, Nafe B, Furia JP, Maffulli N. Eccentric loading, shock-wave treatment or a wait-and-see policy for tendinopathy of the main body of tendon Achilles: A randomized controlled trial. *Am J Sports Med* 2007; 35: 374–383
- 22 Sanchez M, Anitua E, Azofra J, Andia I, Padilla S, Mujika I. Comparison of surgically repaired Achilles tendon tears using platelet-rich fibrin matrices. *Am J Sports Med* 2007; 35: 245–251
- 23 Schepsis AA, Jones H, Haas AL. Achilles tendon disorders in athletes. *Am J Sports Med* 2002; 30: 287–305
- 24 Schnabel LV, Mohammed HO, Miller BJ, McDermott WG, Jacobson MS, Santangelo KS, Fortier LA. Platelet rich plasma (PRP) enhances anabolic gene expression patterns in flexor digitorum superficialis tendons. *J Orthop Res* 2007; 25: 230–240
- 25 Steenstra E, van Dijk CN. Achilles tendoscopy. *Foot Ankle Clin* 2006; 11: 429–438
- 26 Vulpiani MC, Guzzini M, Ferretti A. Operative treatment of chronic Achilles tendinopathy. *Int Orthop* 2003; 27: 307–310
- 27 Weibrich G, Kleis WK, Hafner G, Hitzler WE, Wagner W. Comparison of platelet, leukocyte, and growth factor levels in point-of-care platelet-enriched plasma, prepared using a modified Curasan kit, with preparations received from a local blood bank. *Clin Oral Implants Res* 2003; 14: 357–362
- 28 Wheelless' Textbook of Orthopaedics, Achilles Teninitis – Tendinosis. <http://www.wheelsonline.com/> updated January 23 2009
- 29 Woodley BL, Newsham-West RJ, Baxter GD. Chronic tendinopathy: effectiveness of eccentric exercise. *Br J Sports Med* 2007; 41: 188–198
- 30 Zanetti M, Metzdorf M, Kundert HP, Zollinger H, Vienne P, Seifert B, Hodler J. Achilles tendons: Clinical relevance of neovascularisation diagnosed with Power Doppler US. *Radiology* 2003; 227: 556–560